



2025

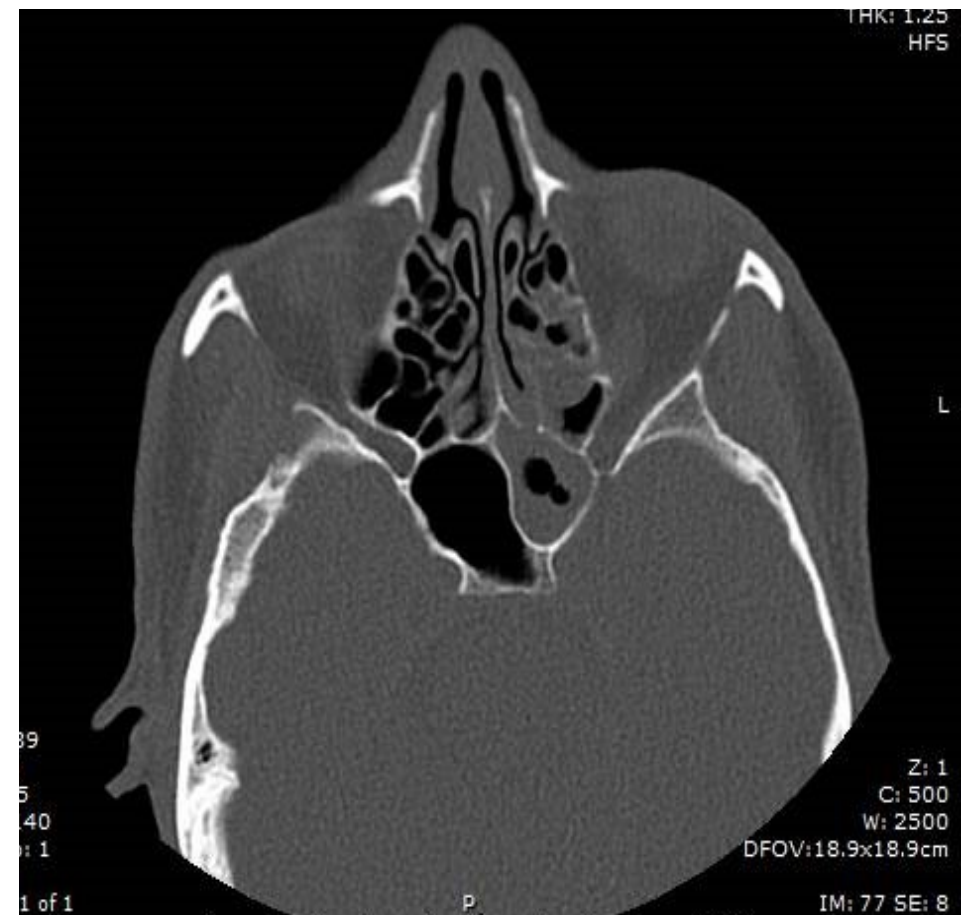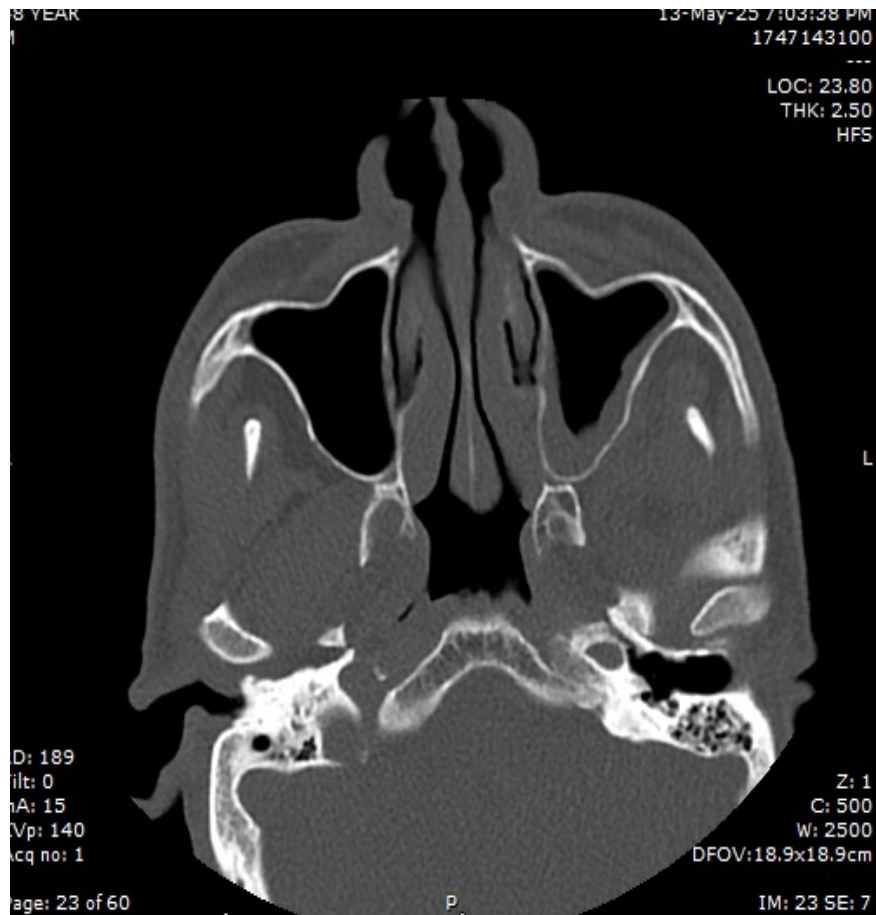
KARNATAKA RADIOLOGY EDUCATION PROGRAM

- Name-XYZ
- Age-48 years
- Sex-Male

CHIEF COMPLAINTS:

- **Nasal congestion ,headache ,swelling on left side of the face since 1 week .**
- **No other comorbidities**
- **No significant family history**

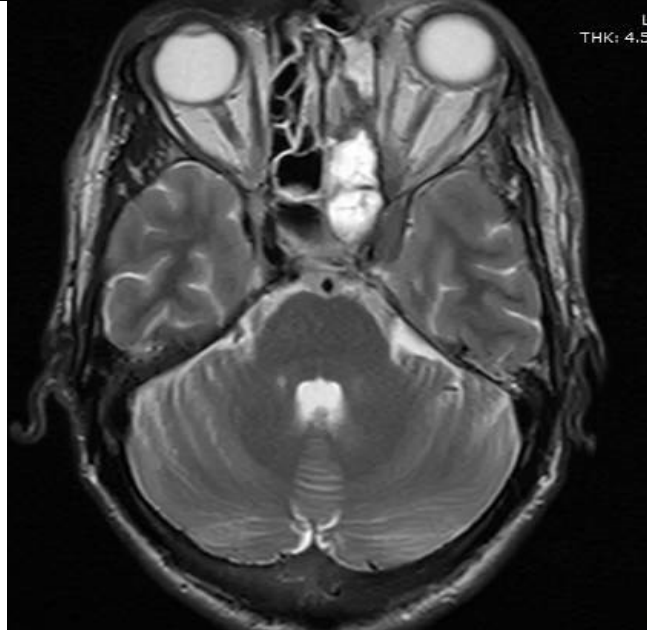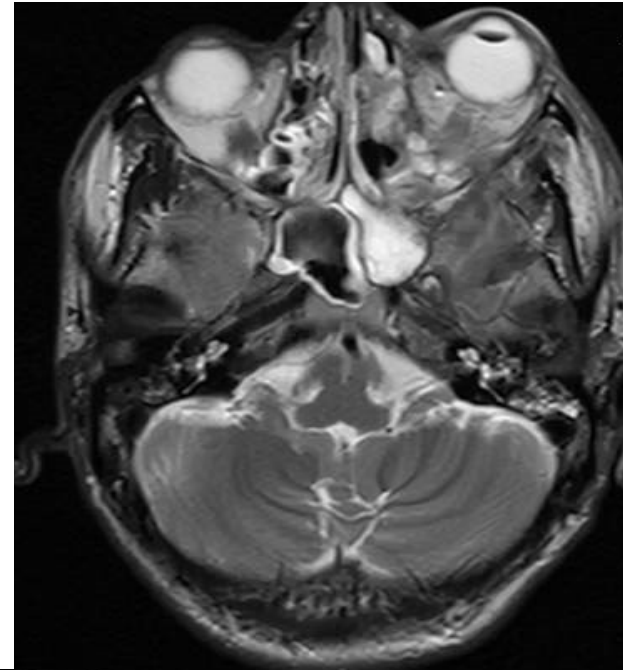
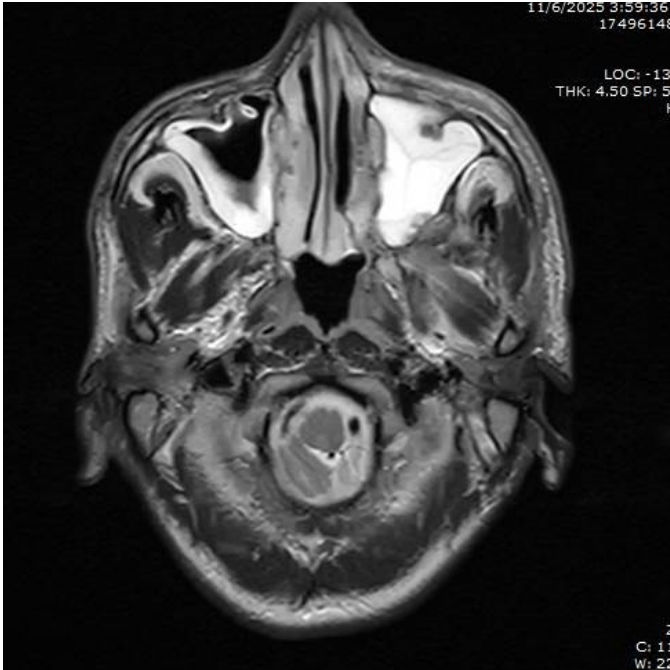
CT PNS

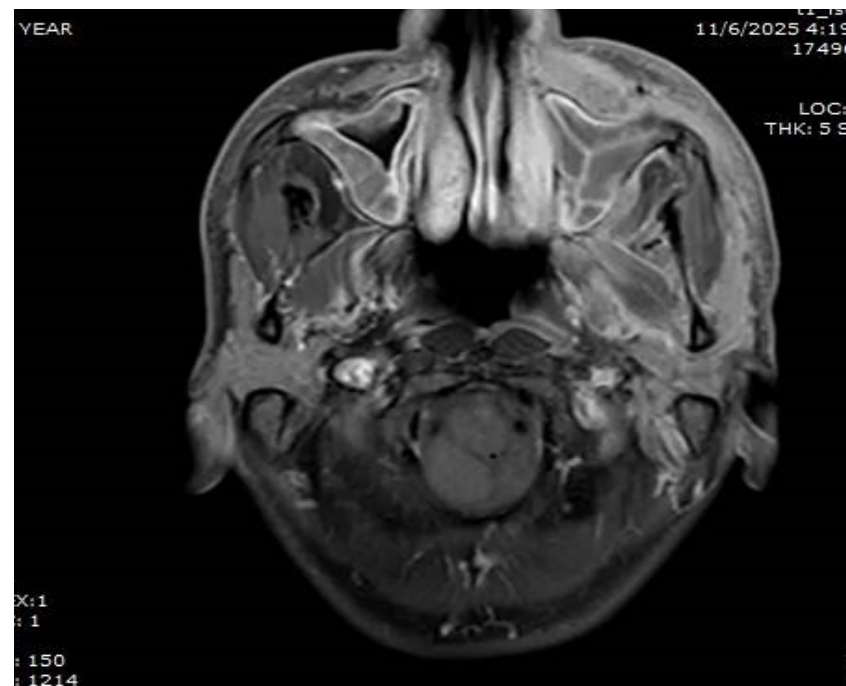
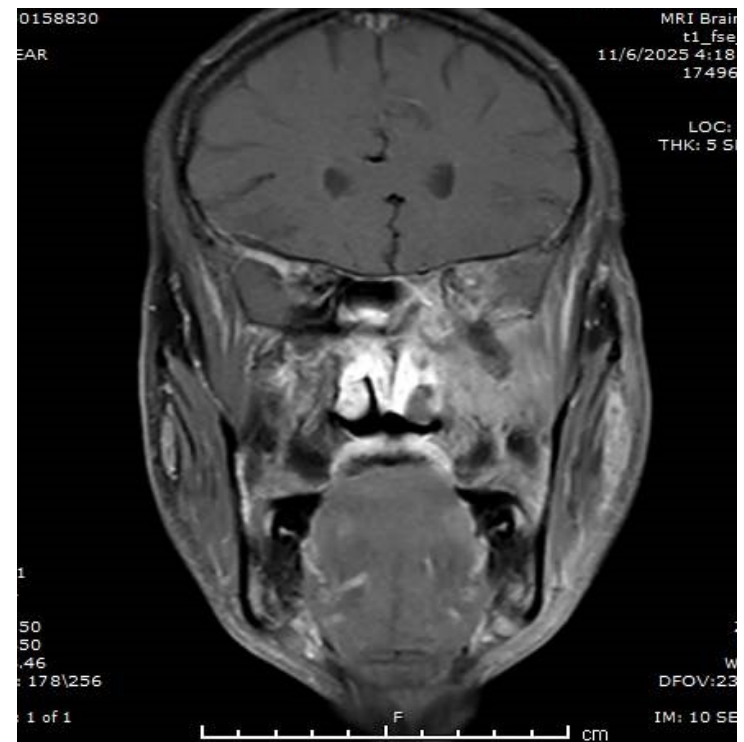
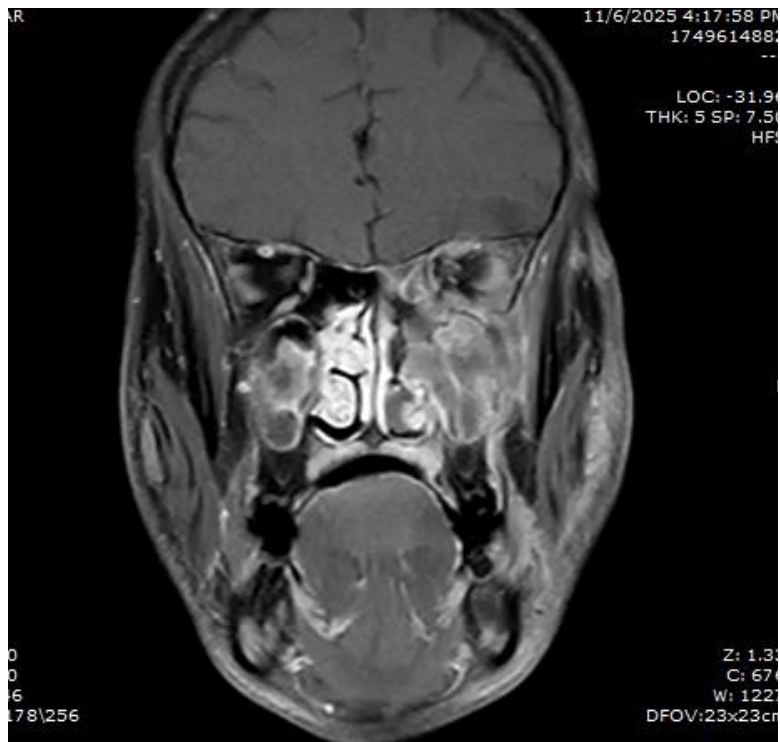
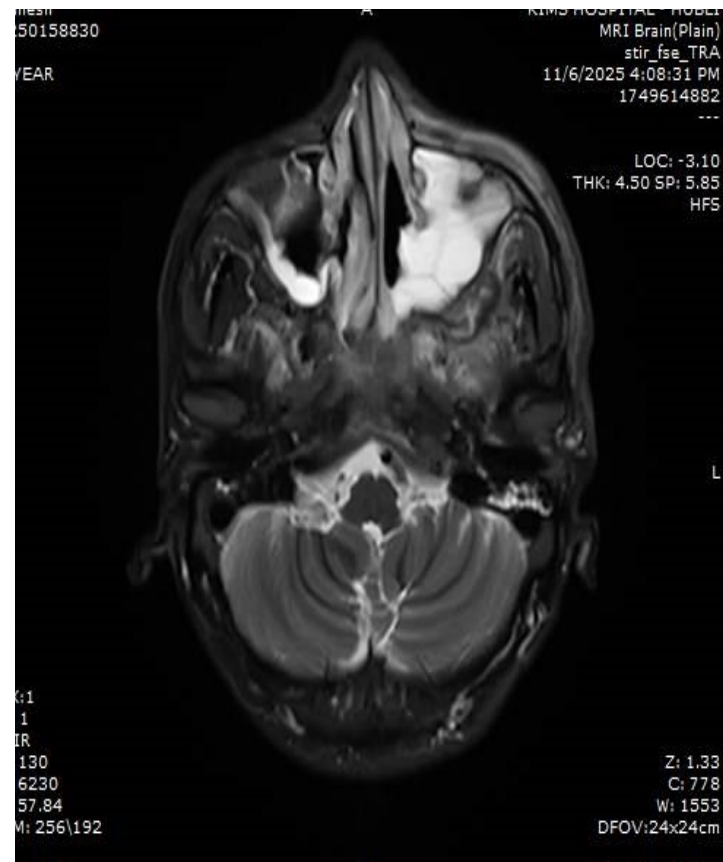
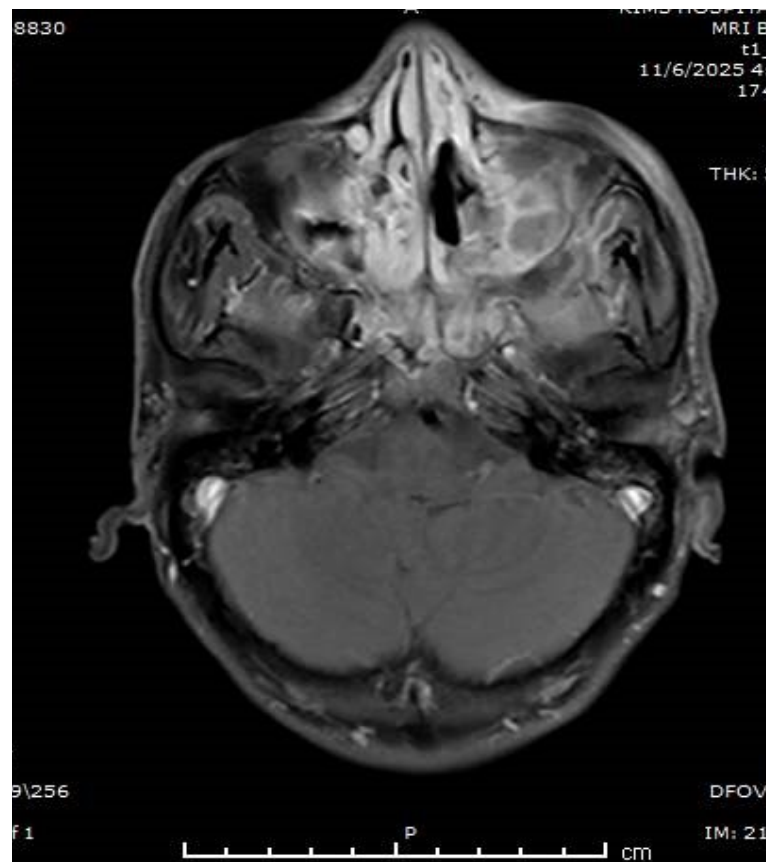
CT FINDINGS

- **IRREGULAR MUCOSAL THICKENING INVOLVING LEFT MAXILLARY SINUS, ETHMOIDAL AND SPHENOIDAL SINUS --> LIKELY PANSINUSITIS.**

MRI







MRI FINDINGS

- EVIDENCE OF MUCOSAL THICKENING NOTED ALONG LEFT MAXILLARY SINUS WITH INVOLVEMENT OF ANTERIOR, POSTERIOR ETHMOID AND SPHENOID SINUSES.
- T2/FLAIR HYPERINTENSE SIGNAL NOTED ALONG LEFT RETRO ANTRAL REGION WITH DIFFUSION RESTRICTION NOTED ALONG POSTERIOR MAXILLARY SINUS WALL. ON POST CONTRAST IMAGING DECREASED ENHANCEMENT SEEN ALONG INFERIOR MAXILLARY SINUS WALL AND INFERIOR TURBINATE APPEARS HYPOENHANCING ? BLACK TURBINATE SIGN POSITIVE. DIFFUSE PERIANTRAL FATSTRANDING NOTED F/S/O LEFT MAXILLARY ETHMOID AND SPHENOID FUNGAL SINUSITIS.

IMPRESSION

FUNGAL SINUSITIS WITH BLACK TURBINATE POSITIVE

MENTORS

Dr.J.G Suttagatti

HOD AND PROFESSOR

DEPT OF RADIODIAGNOSIS

KMCRI HUBLI

Dr.G C PATIL

PROFESSOR

DEPT OF RADIODIAGNOSIS

KMCRI HUBLI

All Professor and teaching staff,dept of radiodiagnosis KMCRI HUBLI